



The Gawler Foundation

An integrated approach to health
healing and wellbeing

MEDIA ALERT

Medical Journal of Australia reports on Ian Gawler's remarkable recovery

A recent edition of the Medical Journal of Australia has published a 30 year follow up on Dr Ian Gawler's remarkable recovery from a virulent bone cancer, osteogenic sarcoma.

Using a combination of self-help measures, including diet and meditation, Ian was able to turn around a prognosis of 2-3 weeks survival into 30 years of being cancer free.

The MJA report said "such a lifestyle approach, incorporating meditation and a vegan diet, has recently been shown to cause significant modulation of gene expression and biological processes associated with tumour growth."¹

Dr Gawler was a young veterinary surgeon and decathlon athlete when he was diagnosed with osteogenic sarcoma.

The amputation of his leg failed to arrest the spread of the disease and doctors gave him a matter of weeks to live.

This 30 year follow up was written by **Prof George Jelinek**, MBSS, MD, DipDHM, FACEM, Professor of Emergency Medicine at Sir Charles Gairdner Hospital and the University of Western Australia and **Dr Ruth Gawler**, MB BS, MGPPsych, FACPsyMed, General Practitioner and Therapist.

"It is interesting to consider the possible factors involved in this man's remarkable recovery," the report said.

"Spontaneous remission is a possibility, although exceedingly unlikely at such an advanced stage of disease, and its coincident timing with a wide range of self-help measures adopted by the patient makes this explanation even more improbable. Certainly, the patient had widespread disease from which recovery, even today, would be very unlikely.

"...The patient attributed the remarkable recovery to intensive meditation, and it is true that the patient meditated from 3 to 5 hours daily after developing secondaries. He still regularly meditates and teaches others with cancer to do so. His fastidious adoption of the Gerson diet² for 3 months, followed by adherence to a plant-based wholefood vegan diet may also have played some part."

ENDS

Prof Jelinek and Dr Gawler are available for interview.

The MJA article, *Thirty-year follow-up at pneumonectomy of a 58-year-old survivor of disseminated osteosarcoma* by George A Jelinek & Ruth H Gawler follows.

¹ Ornish D, Magbanua MJ, Weidner G, et al. Changes in prostate gene expression in men undergoing an intensive nutrition and lifestyle intervention. *Proc Natl Acad Sci U S A* 2008; 105: 8369-8374.

² Gerson M. A cancer therapy: results of fifty cases. New York: Station Hill Press, 1995

Thirty-year follow-up at pneumonectomy of a 58-year-old survivor of disseminated osteosarcoma

George A Jelinek and Ruth H Gawler

A 1978 case report in the Journal described a 25-year-old man with disseminated osteogenic sarcoma whose metastases regressed after treatment with diet and intensive meditation. Thirty years later, there has been no recurrence of his cancer, and a recent pneumonectomy for chronic bronchiectasis revealed mature cancellous bone in the resected lung. The man is otherwise well. (MJA 2008; 189: 663-665)

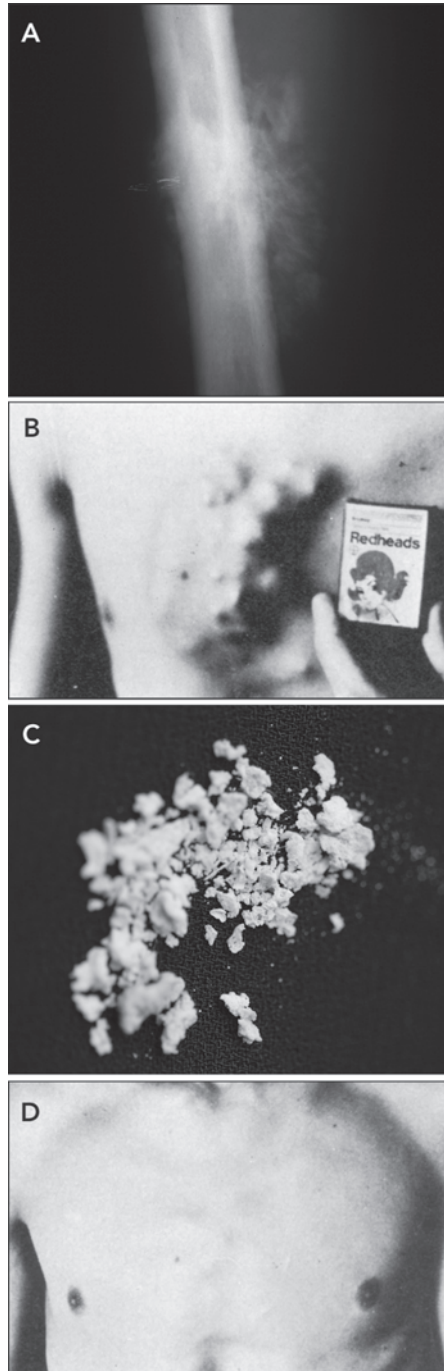
Clinical record

A man who is now 58 years old was diagnosed in 1974, at the age of 24, with histologically confirmed high-grade osteogenic sarcoma of the right femur (Figure, A). His right leg was amputated in January 1975. Histopathologically, the tumour was described (in a 1994 review of the case) as follows: "The tissue is replaced by a cellular malignant spindle cell tumour forming osteoid and bone and having a disorganised pattern of proliferation ... confirming the diagnosis of a high grade endosteal osteosarcoma (osteogenic sarcoma)."

In December 1975, widespread bony and pulmonary metastases were diagnosed. Despite being told in March 1976 that he had only 2–3 weeks to live, the man survived until September that year, when he underwent three cycles of palliative chemotherapy with vincristine, adriamycin, cyclophosphamide and dacarbazine, as well as brief palliative radiation therapy. He elected to discontinue these therapies as his condition deteriorated further.

The patient then consulted prominent psychiatrist and hypnotherapist Dr Ainslee Meares, who reported his case and his subsequent remarkable recovery in the *Medical Journal of Australia* in 1978.¹ When Meares first saw the patient, he had visible bony tumours protruding from his ribs, sternum (Figure, B) and iliac crest, and was coughing up blood containing small spicules of bone (Figure, C). Meares taught him how to meditate, and both he and the patient felt this was a key component in recovery, although he also adhered faithfully to a vegan diet and tried many alternative therapies, including massage, acupuncture, faith healing and others.

The patient recovered and returned to full-time work, founding and running self-help groups for people with cancer, but had persistent reminders of the original illness. Presumably related to immunosuppression from chemotherapy, he developed pulmonary



tuberculosis in June 1978, and was treated for this condition for 12 months. This progressed to cavitation and severe bronchiectasis, causing repeated bouts of pneumonia and persistently elevated erythrocyte sedimentation rate (ESR).

Chest x-rays in November 1989, 15 years after the patient's diagnosis and subsequent recovery, showed evidence of previous tuberculosis and ongoing bronchiectasis, with a left hilar mass compressing the left upper lobe bronchus by 50%. Views of the lumbar spine and pelvis, taken at the same time to investigate ongoing back pain, showed abnormalities initially thought to represent progressive metastatic disease. The report noted "progressive metastatic disease with large osteoblastic deposit right ilium, sacrum, and invasion into L5". That report was amended 4 days later, after comparison with films from 1978, to state "The appearances in the body of L5 ... are those of metastatic disease but this appearance is essentially unchanged". A thoracic computed tomography scan performed a few days later showed evidence of previous left lung tuberculosis.

With no further treatment, the patient's condition remained stable. X-ray images of the chest, pelvis and lumbar spine in 1993 were unchanged from 1989. Lung function testing in 1996 and 1999 showed satisfactory function, with an FEV₁/FVC (forced expiratory volume in 1 second/forced vital capacity) ratio of 2.56 L/3.40 L. Indeed, the patient was well enough to go trekking in Nepal for three weeks in 1999 to a height of about 16 000 feet above sea level.

However, two episodes of left lower lobe pneumonia in 2004 and chronic bronchiectasis resulted in referral to a thoracic surgeon with a view to pneumonectomy. Noting the patient's chronically elevated ESR, indicating ongoing sepsis, and recurrent chest infections, the surgeon recommended left pneumonectomy while the patient was still young enough to tolerate

the surgery. In December 2004, pneumonectomy was performed. As the patient had relied on elbow crutches since the original leg amputation, it was hoped that a minimally invasive approach might preserve chest wall skeletal structure and musculature, but because of widespread adhesions and tuberculous scarring, this was not possible. A complicated 5-hour pleuropneumonectomy was performed, with the pericardium being opened to enable access to the pulmonary veins, precipitating a short period of intraoperative ventricular fibrillation.

Macroscopic pathological examination showed a small, collapsed, scarred left lung. The lung parenchyma was abnormal, and bronchiectasis, cavitation and scarring were widespread, but there was no obvious tumour. Microscopic examination showed severe bronchiectasis, but there was no evidence of mycobacterial infection. The report noted that "palpation of lung parenchyma deep to the hilum reveals a rock-hard consistency, impossible to section with a knife. Using a saw, horizontal cuts . . . reveal a centrally located bony mass 35 × 30 mm about, surrounding the bifurcation of the left main bronchus." Histopathological examination of decalcified sections showed "a bony mass surrounding and incorporating large central bronchi and neurovascular structures. Much of the bone has a mature cancellous appearance with normal appearing osteocytes, and mature fat within the intertrabecular spaces. In addition there are foci of coarse sclerotic and heavily calcified bone which are devoid of viable osteocytes. No viable tumour is present."

After steady postoperative recovery, the patient returned to full-time work and remains well.

Discussion

Osteosarcomas are rare malignant tumours of the skeleton characterised by formation of immature bone by tumour cells. At the time of this patient's diagnosis, osteosarcoma was a devastating disease with very low survival rates.² Most patients died within a year of diagnosis. Management centred around limb amputation, with palliative chemotherapy and radiation therapy for recurrences. Over the past 30 years, management has improved dramatically. With the use of limb-sparing surgery, induction and adjuvant chemotherapy, and surgical excision of metastases, survival rates of around 60% can now be expected for patients presenting with localised disease.³⁻⁵

There are limited data examining long-term outcomes among patients recovering from osteosarcoma. A few articles have reported long-term follow-up, including surveillance for recurrence,⁶ the development of other cancers,⁷ and cardiac toxicity from chemotherapy agents.⁸ Metastases have been known to develop as long as 14 years after diagnosis.⁶ While there is a report of spontaneous regression of a pulmonary metastasis that developed 5 years after treatment for osteosarcoma,⁹ the fate of regressed secondaries has not been well documented.

Today, pulmonary metastases are often resected, but this is while the tumour is active. In this patient's case, the lung was resected, for other reasons, 30 years after the original diagnosis, and incidentally, a large piece of mature cancellous bone was found surrounding the left main bronchus. This presumably represented bone formation by a long-since regressed secondary tumour, similar to the bone found in the primary tumour at the time of amputation.

It is clear from the 1978 report that large sections of the externally visible osteogenic secondaries were resorbed as the cancer regressed. This was most obvious on the patient's chest wall (Figure, D). However, some spinal and pelvic bone formed by the secondaries appears to have remained intact after tumour disappearance, as illustrated by the fact that x-rays taken of the spine and pelvis 15 years after diagnosis and recovery were identical with films of 11 years earlier and by the presence of bone in the resected lung.

It is interesting to consider the possible factors involved in this man's remarkable recovery. Spontaneous remission is a possibility, although exceedingly unlikely at such an advanced stage of disease, and its coincident timing with a wide range of self-help measures adopted by the patient makes this explanation even more improbable. Certainly, the patient had widespread disease from which recovery, even today, would be very unlikely. Although the patient received a short course of palliative chemotherapy and radiotherapy to his lumbar spine, it is unlikely that this would have been curative with such widespread metastatic disease.

Meares and the patient attributed the remarkable recovery to intensive meditation,¹ and it is true that the patient meditated from 3 to 5 hours daily after developing secondaries. He still regularly meditates and teaches others with cancer to do so. His fastidious adoption of the Gerson diet¹⁰ for 3 months, followed by adherence to a plant-based wholefood vegan diet may also have played some part. Such a lifestyle approach, incorporating meditation and a vegan diet, has recently been shown to cause significant modulation of gene expression and biological processes associated with tumour growth.¹¹

Apart from illustrating the value of maintaining hope in the face of apparent hopelessness, this case shows that, long after tumour regression, metastatic lesions from osteosarcoma may contain significant amounts of residual bone. Even in the absence of tumour, these bony deposits may cause health problems in their own right, depending on their location. Our understanding of such unlikely survival continues to improve with the recent demonstration that modifiable lifestyle factors affect gene expression in patients with cancer.¹¹

Acknowledgements

We are grateful to Professor Peter Clarke, who performed the pneumonectomy, and Mr John Doyle, who undertook the amputation, for their assistance with the provision of past records and review of the manuscript, and to Dr Sandra Neate for her critical review and helpful suggestions.

Competing interests

Professor Jelinek is a friend and colleague of the patient, and Dr Gawler is related to the patient.

Author details

George A Jelinek, MD, FACEM, DipDHM, Professorial Fellow^{1,2}
Ruth H Gawler, MB BS, MGPPsych, FACPsMed, General Practitioner and Therapist³

1 Department of Medicine, University of Melbourne, St Vincent's Hospital, Melbourne, VIC.

2 Department of Emergency Medicine, St Vincent's Hospital, Melbourne, VIC.

3 The Gawler Foundation, Yarra Junction, VIC.

Correspondence: George.Jelinek@svhm.org.au

References

- 1 Meares A. Regression of osteogenic sarcoma metastases associated with intensive meditation. *Med J Aust* 1978; 2: 433.
- 2 Picci P. Osteosarcoma (osteogenic sarcoma). *Orphanet J Rare Dis* 2007; 2: 6.
- 3 Jaffe N, Carrasco H, Raymond K, et al. Can cure in patients with osteosarcoma be achieved exclusively with chemotherapy and abrogation of surgery? *Cancer* 2002; 95: 2202-2210.
- 4 Wittig JC, Bickels J, Priebat D, et al. Osteosarcoma: a multidisciplinary approach to diagnosis and treatment. *Am Fam Physician* 2002; 65: 1123-1132.
- 5 Tan JZ, Schlicht SM, Powell GJ, et al. Multidisciplinary approach to diagnosis and management of osteosarcoma — a review of the St Vincent's Hospital experience. *Int Semin Surg Oncol* 2006; 3: 38.
- 6 Strauss SJ, McTiernan A, Whelan JS. Late relapse of osteosarcoma: implications for follow-up and screening. *Pediatr Blood Cancer* 2004; 43: 692-697.
- 7 Kim MS, Sim YS, Lee SY, Jeon DG. Secondary thyroid papillary carcinoma in osteosarcoma patients: report of two cases. *J Korean Med Sci* 2008; 23: 149-152.
- 8 Longhi A, Ferrari S, Bacci G, Specchia S. Long-term follow-up of patients with doxorubicin-induced cardiac toxicity after chemotherapy for osteosarcoma. *Anticancer Drugs* 2007; 18: 737-744.
- 9 Bacci G, Palmerini E, Staals EL, et al. Spontaneous regression of lung metastasis from osteosarcoma: a case report. *J Pediatr Hematol Oncol* 2008; 30: 90-92.
- 10 Gerson M. *A cancer therapy: results of fifty cases*. New York: Station Hill Press, 1995.
- 11 Ornish D, Magbanua MJ, Weidner G, et al. Changes in prostate gene expression in men undergoing an intensive nutrition and lifestyle intervention. *Proc Natl Acad Sci U S A* 2008; 105: 8369-8374.

(Received 2 Sep 2008, accepted 19 Oct 2008)

□